

Visit <http://www.tinyurl.com/EyeOnCataract-3> for online testing and instant CME certificate.

Cataract Case of the Month CME Series

EYE ON CATARACT™

CHALLENGING CASES MADE ROUTINE

This Month's Case

Cataract Surgery in a Patient With Pseudoexfoliation Syndrome

ORIGINAL RELEASE: JANUARY 15, 2016 • **LAST REVIEW:** DECEMBER 9, 2015 • **EXPIRATION:** JANUARY 31, 2017

Program Chair

John Sheppard, MD, MMSc

Professor of Ophthalmology
Eastern Virginia Medical School
President
Virginia Eye Consultants
Norfolk, Virginia

Faculty

Anthony J. Aldave, MD

Associate Professor of Ophthalmology
The Jules Stein Eye Institute
University of California, Los Angeles
Los Angeles, California

Deepinder K. Dhalliwal, MD

Associate Professor of Ophthalmology
Director, Cornea, Cataract, and External Disease Service
Director, Refractive and Laser Surgery Center
Director, UPMC Eye Center Monroeville
Director and Founder, Center of Integrative Eye Care
University of Pittsburgh School of Medicine
Pittsburgh, Pennsylvania

Bonnie An Henderson, MD

Clinical Professor of Ophthalmology
Tufts University School of Medicine
Ophthalmic Consultants of Boston
Boston, Massachusetts

Jay S. Pepose, MD, PhD

Professor of Clinical Ophthalmology
Barnes-Jewish Hospital
Washington University School of Medicine
Medical Director
Pepose Vision Institute
St. Louis, Missouri

William B. Trattler, MD

Volunteer Assistant Professor of Ophthalmology
Bascom Palmer Eye Institute
University of Miami
Director of Cornea
Center for Excellence in Eye Care
Miami, Florida

CME Reviewer for New York Eye and Ear Infirmary of Mount Sinai

Joseph F. Panarelli, MD

Assistant Professor of Ophthalmology
Associate Residency Program Director
New York Eye and Ear Infirmary of Mount Sinai
New York, New York

LEARNING METHOD AND MEDIUM

This educational activity consists of a case discussion and study questions. The participant should, in order, read the learning objectives at the beginning of this case discussion, read the case discussion, answer all questions in the post test, and complete the Activity Evaluation/Credit Request form. To receive credit for this activity, please visit <http://www.tinyurl.com/EyeOnCataract-3> and follow the instructions provided on the post test and Activity Evaluation/Credit Request form. This educational activity should take a maximum of 0.75 hour to complete.

CONTENT SOURCE

This continuing medical education (CME) activity captures content from an expert roundtable discussion held in San Diego, California, on April 16, 2015.

ACTIVITY DESCRIPTION

Cataract surgery is the most commonly performed surgery among adults in the United States, and the number of patients undergoing this procedure is continuing to increase. For patients who are identified as candidates for cataract surgery, optimization of the ocular surface is critical for obtaining optimal patient outcomes. There are a host of new tools that can help cataract surgeons with their preoperative evaluations. Among these are several tests that are useful adjuncts for diagnosing dry eye/meibomian gland dysfunction. The purpose of this activity is to update ophthalmologists on recent advances in the care of patients with cataracts.

TARGET AUDIENCE

This activity is intended for ophthalmologists.

LEARNING OBJECTIVES

Upon completion of this activity, participants will be better able to:

- Select appropriate medication regimens for suppressing postoperative inflammation in high-risk patients
- Demonstrate optimal IOL selection, knowledge of appropriate refractive targets, and understanding of strategies for achieving intended goals
- Describe the benefits of new diagnostic and surgical technologies with application to cataract surgery

ACCREDITATION STATEMENT

This activity has been planned and implemented in accordance with the accreditation requirements and policies of the Accreditation Council for Continuing Medical Education (ACCME) through the joint providership of **New York Eye and Ear Infirmary of Mount Sinai** and **MedEdicus LLC**. The **New York Eye and Ear Infirmary of Mount Sinai** is accredited by the ACCME to provide continuing medical education for physicians.

In July 2013, the Accreditation Council for Continuing Medical Education (ACCME) awarded **New York Eye and Ear Infirmary of Mount Sinai** "Accreditation with Commendation," for six years as a provider of continuing medical education for physicians, the highest accreditation status awarded by the ACCME.

AMA CREDIT DESIGNATION STATEMENT

The **New York Eye and Ear Infirmary of Mount Sinai** designates this enduring material for a maximum of 0.75 **AMA PRA Category 1 Credit™**. Physicians should claim only the credit commensurate with the extent of their participation in the activity.

GRANTOR STATEMENT

This continuing medical education activity is supported through an unrestricted educational grant from Bausch + Lomb Incorporated.

DISCLOSURE POLICY STATEMENT

It is the policy of **New York Eye and Ear Infirmary of Mount Sinai** that the faculty and anyone in a position to control activity content disclose any real or apparent conflicts of interest relating to the topics of this educational activity, and also disclose discussions of unlabeled/unapproved uses of drugs or devices during their presentation(s).

New York Eye and Ear Infirmary of Mount Sinai has established policies in place that will identify and resolve all conflicts of interest prior to this educational activity. Full disclosure of faculty/planners and their commercial relationships, if any, follows.

DISCLOSURES

Faculty had financial agreements or affiliations during the past year with commercial interests as follows:

Dr Aldave: Consultant/Advisory Board: Allergan; Nicox; and TearScience; Honoraria from promotional, advertising or non-CME services received directly from commercial interests or their Agents (eg, Speakers Bureaus); Alcon; and Allergan; Other/Travel Support: Laboratoires Théa; and Tissue Banks International. **Dr Dhalliwal:** Consultant/Advisory Board: AMO Lasers; and NovaBay Pharmaceuticals; Research Grants: Abbott Medical Optics; Avedo; and Eleven Biotherapeutics. **Dr Henderson:** Consultant/Advisory Board: Abbott Medical Optics; Alcon; and Bausch + Lomb. **Dr Pepose:** Consultant/Advisory Board: Abbott Medical Optics; Alcon; Allergan; Bausch + Lomb; Shire; and TearLab; Ownership Interest: Acufocus. **Dr Sheppard:** Consultant/Advisory Board: AbbVie; Alcon; Allergan; Bausch + Lomb; Bio-Tissue; Omeros; TearLab; and TearScience; Honoraria from

promotional, advertising or non-CME services received directly from commercial interests or their Agents (eg, Speakers Bureaus); Alcon; Bausch + Lomb; ScienceBased Health; and TearLab; Ownership Interest: Alphaeon; EyeGate Pharma; OcuHub; Rapid Pathogen Screening; TearLab; and 1-800-Doctors. **Dr Trattler:** Consultant/Advisory Board: Abbott Medical Optics; Alcon; Allergan; and Bausch + Lomb; Contracted Research: Refocus Group; Honoraria from promotional, advertising or non-CME services received directly from commercial interests or their Agents (eg, Speakers Bureaus); Allergan; and OCULUS, Inc; Ownership Interest: Calhoun Vision; XL Ophthalmics; and Rapid Pathogen Screening.

NEW YORK EYE AND EAR INFIRMARY OF MOUNT SINAI PEER REVIEW DISCLOSURE

Joseph F. Panarelli, MD, has no relevant commercial relationships to disclose.

EDITORIAL SUPPORT DISCLOSURES

Cheryl Guttman (writer); **Cynthia Tornallyay, RD, MBA, CHCP**; **Kimberly Corbin, CHCP**; **Barbara Aubel**; **Diane McArdle, PhD**; and **Barbara Lyon** have no relevant commercial relationships to disclose.

DISCLOSURE ATTESTATION

The contributing individuals listed above have attested to the following:

- 1) that the relationships/affiliations noted will not bias or otherwise influence their involvement in this activity;
- 2) that practice recommendations given relevant to the companies with whom they have relationships/affiliations will be supported by the best available evidence or, absent evidence, will be consistent with generally accepted medical practice; and
- 3) that all reasonable clinical alternatives will be discussed when making practice recommendations.

OFF-LABEL DISCUSSION

This CME activity includes discussion of unlabeled and/or investigative uses of drugs. Please refer to the official prescribing information for each drug discussed in this activity for FDA-approved dosing, indications, and warnings.

FOR DIGITAL EDITIONS

System Requirements:

To view this online activity, please ensure the computer you are using meets the following requirements:

- **Operating System:** Windows or Macintosh
- **Media Viewing Requirements:** Flash Player or Adobe Reader
- **Supported Browsers:** Microsoft Internet Explorer, Firefox, Google Chrome, Safari, and Opera
- **A good Internet connection**

New York Eye and Ear Infirmary of Mount Sinai

Privacy & Confidentiality Policies

<http://www.nyee.edu/health-professionals/cme/enduring-activities>

CME Provider Contact Information

For questions about this activity, call 212-979-4383.

TO OBTAIN AMA PRA CATEGORY 1 CREDIT™ for this activity, read the material in its entirety and consult referenced sources as necessary.

We offer instant certificate processing and support Green CME. Please take this post test and evaluation online by going to

<http://www.tinyurl.com/EyeOnCataract-3>. Upon passing, you will receive your certificate immediately. You must score 70% or higher to receive credit for this activity, and may take the test up to 2 times. Upon registering and successfully completing the post test, your certificate will be made available online and you can print it or file it.

There are no fees for participating in and receiving CME credit for this activity.

DISCLAIMER

The views and opinions expressed in this educational activity are those of the faculty and do not necessarily represent the views of **New York Eye and Ear Infirmary of Mount Sinai**, **MedEdicus LLC**, **Bausch + Lomb Incorporated**, or *Ophthalmology Times*.

Jointly provided by **New York Eye and Ear Infirmary of Mount Sinai** and **MedEdicus LLC**



This CME activity is copyrighted to MedEdicus LLC ©2016. All rights reserved.

Cataract Surgery in a Patient With Pseudoexfoliation Syndrome

John Sheppard, MD, MMSc; Anthony J. Aldave, MD; Deepinder K. Dhaliwal, MD; Bonnie An Henderson, MD; Jay S. Pepose, MD, PhD; William B. Trattler, MD

Case from the files of Bonnie An Henderson, MD

A 76-year-old woman presents with pseudoexfoliation glaucoma (PXG) OU that is being treated with latanoprost, 0.005%, 1 drop in each eye at bedtime. Optic nerve examination shows a cup-to-disc ratio of 0.7 and vertical elongation with superior thinning.

Her best corrected visual acuity is 20/60 and intraocular pressure (IOP) is 18 mm Hg, with a maximum of 23 mm Hg. On slit-lamp examination, fibrillar deposits are noted on the anterior lens capsule, and she has a significant cataract (NO3NC3), but no evidence of phacodonesis. Notably, however, non-contact optical biometry shows anterior chamber depth (ACD) measurements of 2.68 mm OD and 2.40 mm OS.

Pseudoexfoliation syndrome (PXF) is common in the cataract surgery population because it is an age-related disorder that increases the risk for glaucoma and the incidence of cataracts.^{1,2} Pseudoexfoliation syndrome also increases the risk for various complications during and after cataract surgery (Table 1).³ Therefore, it is important that surgeons recognize PXF preoperatively so that they can implement the best strategies to manage these challenges.

Table 1. Cataract Surgery Challenges and Risks in Eyes With Pseudoexfoliation Syndrome

Intraoperative	Postoperative
Poor pupil dilation	Intraoperative pressure spikes
Zonular weakness	Prolonged inflammation
Capsular rent/rupture	Capsular phimosis
	IOL subluxation/dislocation

Abbreviation: IOL, intraocular lens.

Whereas the diagnosis of PXF was already established in this patient, in some cases, PXF can be subtle. A good way to visualize the fibrillar deposits on the anterior capsule is to retroilluminate the eye through a dilated pupil. Subtle deposits become obvious. Gonioscopy is also helpful for identifying PXF because there is

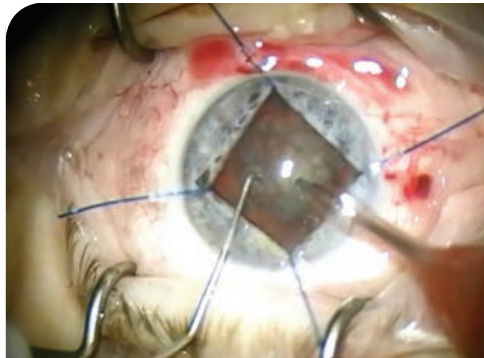


Figure 1. Iris hooks for pupillary dilation.




Figure 2. Inferiorly dislocated intraocular lens and capsular bag complex in a patient with PXF.

Images Courtesy of Bonnie An Henderson, MD

usually pigment in the trabecular meshwork and around the Schwalbe line. Surgeons should be aware that PXF is usually a bilateral condition, although it can be asymmetric.³

INTRAOPERATIVE MANAGEMENT OF RISKS

Poor pupil dilation. Eyes with PXF may have small, poorly dilating pupils that will make surgery more challenging. Use of a topical nonsteroidal anti-inflammatory drug (NSAID) preoperatively will help minimize pupil constriction intraoperatively. NSAIDs can be administered topically before surgery or added into the infusion in combination with phenylephrine using a commercially available product approved for intracameral administration. In addition, surgeons can employ strategies for pupil enlargement,

including viscodilation with ophthalmic viscosurgical devices (OVDs), combining a highly cohesive agent that will open the pupil and maintain space in the anterior chamber with a dispersive OVD that will coat the endothelium and be retained during manipulation, insertion of iris hooks (Figure 1), or placement of a pupil expansion ring.

Zonular weakness. Zonular weakness is a primary concern when performing cataract surgery in eyes with PXF because it can lead to lens dislocation and vitreous loss. Phacodonesis noted preoperatively is a sign of zonular weakness and can be detected with or without dilation. Phacodonesis was not observed in this patient, although she did manifest with an intereye difference in ACD, which is another clue to zonular weakness. Anecdotally, either eye can have zonular weakness because the laxity can cause the lens to sit more anteriorly or posteriorly.

Placement of a device to support the capsule and facilitate safe surgery should be done in eyes with zonular insufficiency. Options include standard flexible iris hooks and capsular retention rings. Modified iris hooks in which the hook has a wider angle will encompass both the iris and anterior capsulorhexis and may be particularly useful for eyes with PXF.

Several different types of capsule-retaining devices for expanding the capsular bag are also available; they differ in design, indications for use, and the timing of their insertion during the procedure. The most commonly used is the standard round capsular tension ring (CTR) that helps maintain capsular bag expansion. However, once the CTR is placed, the remaining epinucleus and cortex are often difficult to remove because of the pressure exerted by the CTR against the capsular bag. Alternatively, a modified CTR, which is an open C-shaped loop with 8 equally spaced indentations of 0.15 mm, can be used when a significant amount of lens or cortical material remains. The indentations, which are gap spaces where the CTR is not exerting pressure against the capsular bag, allow for easier removal of the residual material.





Although some surgeons choose to use a CTR in every PXF patient, such routine use is unnecessary and represents overuse of expensive technology. In addition, while a permanently placed CTR increases capsule stability in the short term, it does not prevent late intraocular lens (IOL) dislocation^{4,5} (Figure 2).

Prolonged inflammation. Eyes with PXF are also at risk for increased and prolonged inflammation after cataract surgery, particularly if a pupil expansion device was used. With that in mind, we recommend starting a topical NSAID preoperatively and continuing its use for a longer duration than usual after surgery, perhaps up to 3 months in high-risk patients. Although the exact timing for initiating NSAID use is controversial, prospective comparative trials have shown better outcomes when the treatment was started 3 days prior to surgery than when started 1 day prior to surgery or when there was no pretreatment.⁶⁻⁸ There may also be a need for increased use of a topical corticosteroid to control postoperative inflammation in eyes with PXF, but patients should be closely monitored for IOP response.

It is worth mentioning that the patient in this case was using latanoprost for treatment of her PXG. After topical prostaglandin analogues became available, reports emerged associating them with the development of cystoid macular edema (CME) and pseudophakic CME.^{9,10} On the basis of that information, some cataract surgeons were stopping prostaglandin analogues prior to cataract surgery and for up to 1 month after the procedure. That practice, however, was common in the era before NSAIDs came into widespread use for controlling postoperative inflammation; glaucoma specialists today do not advocate withholding prostaglandin analogue treatment in patients undergoing cataract surgery.

Anterior capsule phimosis. As another consequence of zonular weakness, eyes with PXF are more prone to anterior capsule phimosis after cataract surgery. That risk provides another reason to create a more generously sized capsulorhexis that will allow an adequate visual aperture, even with some contraction. Recognizing the potential for phimosis also underscores the importance of more frequent postoperative follow-up to enable its early identification and timely intervention. When identified early, anterior

capsular phimosis can be treated by using an Nd:YAG laser to create cruciate incisions through the circumferential anterior capsule band to relax the contraction forces.

SURGICAL TECHNIQUES

Capsulotomy. Considering the potential for IOL subluxation/dislocation in eyes with PXF, some surgeons may aim for a smaller size capsulotomy according to the idea that it will help to maintain good IOL position. However, it is better to create a larger capsulotomy that will make cataract removal easier, minimize zonule stress, and decrease the risk for postoperative capsule phimosis.³ Using a femtosecond laser that allows precise sizing of the capsulotomy and assuming an optic size of 6.0 mm, we consider a diameter of 5.3 to 5.5 mm optimal for enabling safe surgery without compromising IOL stability postoperatively in eyes with PXF.

For surgeons who are performing capsulorhexis manually, use of trypan blue to stain the capsule helps improve visualization of the capsule and has an added advantage of increasing capsule stiffness,¹¹ making it easier and safer to initiate and propagate the capsular tear.

OVDs. Ophthalmic viscosurgical devices are a valuable adjunct for enabling safe and successful cataract surgery in eyes with PXF in which there may be increased concerns about the need for corneal endothelial protection, anterior chamber maintenance, pupil dilation, lack of capsular support during nucleus and cortex removal, and expansion of the capsular bag during IOL implantation. Various types of OVDs can be used to support different needs for each step of the procedure.⁴ A dispersive OVD can be useful for sequestering areas of zonule dialysis or vitreous prolapse while also protecting the endothelium. A cohesive OVD can be useful for cleaving cortex from the epinucleus and capsule as well as for maintaining space and pupil viscodilation.

Meticulous removal of the OVD at the end of the procedure is also critical in these cases that are already at increased risk for postoperative IOP spikes. This is particularly true with the use of high-molecular-weight OVDs that have the greatest potential to cause a significant and prolonged IOP elevation when left in the eye.^{12,13} Even with meticulous viscoelastic removal, the IOP is often elevated in the early postoperative period in patients with PXG.³ Medication to

prevent IOP spikes should be considered for use during the first 24 hours after surgery to prevent this occurrence, especially in high-risk eyes with moderate to advanced glaucoma.³

Femtosecond laser-assisted cataract surgery. Using a femtosecond laser-assisted technique for cataract surgery in eyes with PXF offers several potential advantages over manual techniques. As mentioned, laser capsulotomy avoids the challenges faced with manual creation and delivers an accurately sized and centered opening. In addition, laser lens fragmentation increases surgical efficiency by reducing exposure of the eye to ultrasound energy.^{13,14}

Small pupils do not preclude the use of the femtosecond laser if the surgeon implements strategies to achieve adequate pupil dilation.¹⁵ Concern about IOP elevation with docking of the eye to the laser is not a legitimate reason to exclude use of a femtosecond laser in an eye with PXF/PXG, considering that the magnitude of IOP elevation and its duration are much greater during phacoemulsification than during femtosecond laser treatment.

IOL DECISIONS

Both IOL material and design can potentially influence the risk for anterior capsular phimosis and posterior capsule opacification. In the absence of a CTR, a 3-piece IOL will serve better than a single-piece lens for keeping the bag expanded, but a single-piece IOL constructed of a stiffer hydrophobic acrylic material may also work well.

The potential for late in-the-bag IOL dislocation, however, may be the main issue to consider in IOL selection. Although this event can occur with all types of posterior chamber IOLs and is not prevented by a CTR,⁵ a 3-piece IOL may be preferred for in-the-bag implantation because it will allow for IOL repositioning by iris suture fixation, thus avoiding a much more extensive IOL exchange procedure that could be more traumatic to the corneal endothelium.

There are also reasons to consider an anterior chamber (AC) IOL for primary or secondary implantation in eyes with PXF. In a patient with PXG, however, the cataract surgeon should consult with the patient's glaucoma specialist before placing an AC IOL. Its use may be acceptable in a patient with open-angle glaucoma that is well controlled, and

particularly in an older patient in whom there is less concern about long-term outcomes. But an AC IOL might be considered a poor choice for a patient considered at greater risk for needing future glaucoma surgery, such as a person with angle compromise or one whose glaucoma already necessitates treatment with multiple medications.

IOP CONTROL IN PXF/PXG

Pseudoexfoliation syndrome is the most common identifiable cause of open-angle glaucoma,¹⁶ and performing combined glaucoma surgery in eyes with PXG undergoing cataract surgery can be considered. Because cataract surgery itself can result in significant and sustained IOP reduction in eyes with PXF or PXG,¹⁷ particularly if the procedure is combined with an ab interno microinvasive glaucoma surgery (MIGS) procedure, some patients may no longer need to use a topical ocular hypotensive postoperatively. On the other hand, use of more intensive or prolonged corticosteroid treatment postoperatively to control inflammation in eyes with PXF may necessitate continuation of IOP-lowering medication.

At present, 2 MIGS procedures have been approved by the US Food and Drug Administration: (1) ab interno trabeculectomy using a microelectrocautery device to remove a small amount of tissue from the trabecular meshwork and inner wall of the Schlemm canal and (2) placement of a trabecular microbypass microstent into the Schlemm canal. Other approaches that are still investigational include a Schlemm canal scaffold, a suprachoroidal stent for improving uveoscleral outflow, and a soft collagen implant for optimizing aqueous drainage to the subconjunctival space. Both of the currently available MIGS procedures are very learnable for cataract surgeons, and their adoption can offer an excellent opportunity for practice growth.

Studies evaluating the effect of phacoemulsification itself on IOP in eyes with PXF or PXG report reductions ranging from 1.1 to 5.6 mm Hg, with a slight decrease in medication use and an increased likelihood of postoperative IOP spikes.¹⁶ A meta-analysis of studies investigating the trabecular microbypass microstent plus phacoemulsification in populations that include eyes with PXF found that the combined procedure results in significantly greater reductions in IOP and

glaucoma medication use compared with phacoemulsification alone.¹⁸ Results of a prospective nonrandomized study of ab interno trabeculectomy found that in eyes with PXF, mean IOP at 1 year was lowered by 12.3 mm Hg from a baseline of 29.0 mm Hg.¹⁹ Intraocular pressure-lowering was greater in eyes with PXF than in those without PXF and lower when the trabeculectomy procedure was combined with cataract surgery.

However, the effects of MIGS procedures on IOP are relatively modest compared with those of traditional glaucoma surgeries, and so MIGS may be an option to consider for decreasing the medication burden in patients with mild or perhaps moderate glaucoma. Hypothetically, MIGS may be particularly attractive for eyes with PXF, considering evidence that such eyes respond less well to topical IOP-lowering medications than do eyes with primary open-angle glaucoma.⁵ MIGS procedures, however, may not be appropriate for eyes with more advanced glaucoma that require a lower target IOP.

The staging of cataract surgery and glaucoma surgery can differ according to the type and severity of the glaucoma. For example, in eyes with narrow-angle or primary angle-closure glaucoma, cataract surgery alone may open the angle and result in similar or greater IOP lowering with less morbidity than will combined cataract/trabeculectomy surgery.^{20,21}

SUMMARY

Cataract surgery in the setting of PXF is challenging because PXF is associated with denser cataracts, poor pupil dilation, loose zonules, elevated IOP, capsular phimosis, and prolonged postoperative inflammation. It is important for surgeons to recognize PXF preoperatively by carefully examining for the telltale signs of anterior capsular and pupillary margin deposits, heavy pigmentation in the angle, and phacodonesis. Occasionally, however, lens instability during surgery is the first clue to the diagnosis.

To optimize the safety and success of cataract surgery in eyes with PXF, surgeons should take advantage of the benefits of the various OVDs, use mechanical and pharmacologic pupillary dilation techniques as needed, implement appropriate strategies for capsular support, and control IOP and inflammation postoperatively.

REFERENCES

- Ekström C, Botling Taube A. Pseudoexfoliation and cataract surgery: a population-based 30-year follow-up study [published online ahead of print June 11, 2015]. *Acta Ophthalmol*. doi:10.1111/aos.12789.
- Kanthan GL, Mitchell P, Burlutsky G, Rochtchina E, Wang JJ. Pseudoexfoliation syndrome and the long-term incidence of cataract and cataract surgery: the Blue Mountains Eye Study. *Am J Ophthalmol*. 2013;155(1):83-88.e1.
- Shingleton BJ, Crandall AS, Ahmed II. Pseudoexfoliation and the cataract surgeon: preoperative, intraoperative, and postoperative issues related to intraocular pressure, cataract, and intraocular lenses. *J Cataract Refract Surg*. 2009;35(6):1101-1120.
- Lorente R, de Rojas V, Vázquez de Parga P, et al. Management of late spontaneous in-the-bag intraocular lens dislocation: retrospective analysis of 45 cases. *J Cataract Refract Surg*. 2010;36(8):1270-1282.
- Liu E, Cole S, Werner L, Hengerer F, Mamalis N, Kohnen T. Pathologic evidence of pseudoexfoliation in cases of in-the-bag intraocular lens subluxation or dislocation. *J Cataract Refract Surg*. 2015;41(5):929-935.
- Donnenfeld ED, Perry HD, Wittmann JR, Solomon R, Nattis A, Chou T. Preoperative ketorolac tromethamine 0.4% in phacoemulsification outcomes: pharmacokinetic-response curve. *J Cataract Refract Surg*. 2006;32(9):1474-1482.
- Roberts CW. Pretreatment with topical diclofenac sodium to decrease postoperative inflammation. *Ophthalmology*. 1996;103(4):636-639.
- Yavas GF, Öztürk F, Küsbeci T. Preoperative topical indomethacin to prevent pseudophakic cystoid macular edema. *J Cataract Refract Surg*. 2007;33(5):804-807.
- Moroi SE, Gottfredsdottir MS, Scheingart MT, et al. Cystoid macular edema associated with latanoprost therapy in a case series of patients with glaucoma and ocular hypertension. *Ophthalmology*. 1999;106(5):1024-1029.
- Henderson BA, Kim JY, Ament CS, Ferrufino-Ponce ZK, Grabowska A, Cremers SL. Clinical pseudophakic cystoid macular edema. Risk factors for development and duration after treatment. *J Cataract Refract Surg*. 2007;33(9):1550-1558.
- Haritoglou C, Maueil S, Schumann RG, et al. Increase in lens capsule stiffness caused by vital dyes. *J Cataract Refract Surg*. 2013;39(11):1749-1752.
- Holzer MP, Tetz MR, Auffarth GU, Welt R, Völcker HE. Effect of Healon5 and 4 other viscoelastic substances on intraocular pressure and endothelium after cataract surgery. *J Cataract Refract Surg*. 2001;27(2):213-218.
- Reddy KP, Kandulla J, Auffarth GU. Effectiveness and safety of femtosecond laser-assisted lens fragmentation and anterior capsulotomy versus the manual technique in cataract surgery. *J Cataract Refract Surg*. 2013;39(9):1297-1305.
- Mayer WJ, Klapproth OK, Hengerer FH, Kohnen T. Impact of crystalline lens opacification on effective phacoemulsification time in femtosecond laser-assisted cataract surgery. *Am J Ophthalmol*. 2014;157(2):426-432.e1.
- Conrad-Hengerer I, Hengerer FH, Schultztz T, Dick HB. Femtosecond laser-assisted cataract surgery in eyes with a small pupil. *J Cataract Refract Surg*. 2013;39(9):1314-1320.
- Ritch R, Schlötzer-Schrehardt U. Exfoliation syndrome. *Surv Ophthalmol*. 2001;45(4):265-315.
- Chen PP, Lin SC, Junk AK, Radhakrishnan S, Singh K, Chen TC. The effect of phacoemulsification on intraocular pressure in glaucoma patients: a report by the American Academy of Ophthalmology. *Ophthalmology*. 2015;122(7):1294-1307.
- Malvankar-Mehta MS, Iordanou Y, Chen YN, et al. iStent with phacoemulsification versus phacoemulsification alone for patients with glaucoma and cataract: a meta-analysis. *PLoS One*. 2015;10(7):e0131770.
- Ting JL, Damji KF, Stiles MC; Trabectome Study Group. Ab interno trabeculectomy: outcomes in exfoliation versus primary open-angle glaucoma. *J Cataract Refract Surg*. 2012;38(2):315-323.
- Senthil S, Chinta S, Rao HL, et al. Comparison of cataract surgery alone versus cataract surgery combined with trabeculectomy in the management of phacomorphic glaucoma [published online ahead of print January 30, 2015]. *J Glaucoma*. doi:10.1097/JG.0000000000000229.
- Tham CC, Leung DY, Kwong YY, Li FC, Lai JS, Lam DS. Effects of phacoemulsification versus combined phaco-trabeculectomy on drainage angle status in primary angle closure glaucoma (PACG). *J Glaucoma*. 2010;19(2):119-123.

